Received: 25 October 2021 | Accepted: 17 January 2022
DOI: 10.1111/jocd.14798

JCD Journal of Cosmetic Dermatology WILEY

ORIGINAL ARTICLE

Effect of Endolift laser on upper eyelid and eyebrow ptosis treatment

Mohammad Ali Nilforoushzadeh MD[1,2] | Maryam Heidari-Kharaji PhD[1,2,3] | Elham Behrangi MD[4] | Elaheh Lotfi MD[1] | Masoumeh Roohaninasab MD[4] | Maryam Nouri MD[1,2] | Niloufar Najar Nobari MD[4]

[1]Skin and Stem Cell Research Center, Tehran University of Medical Sciences, Tehran, Iran

[2]Jordan Dermatology and Hair Transplantation Center, Tehran, Iran

[3]Institut National de la Recherche Scientifique (INRS)-Centre Armand-Frappier Santé Biotechnologie (CAFSB), Laval, Quebec, Canada

[4]Department of Dermatology, Rasool Akram Medical Complex, Iran University of Medical Sciences, Tehran, Iran

Correspondence
Niloufar Najar Nobari, Department of Dermatology, Rasool Akram Medical Complex, Iran University of Medical Sciences, Tehran, Iran.
Email: Nobarii.ni@gmail.com

Abstract

Drooping of the upper eyelid and eyebrow (ptosis) is common among people and cause the patients dissatisfaction. Various methods have been developed to treatment of the upper eyelid and eyebrow ptosis. However, the current methods focus on surgery to improve the disorder. But patients are worried about the risks of the procedure, and seeking for a non-invasive alternative method. Therefore, non-invasive methods with consistent efficient improvement are needed, especially for middle-aged patients. This study was conducted of 9 patients who underwent the upper eyelid and eyebrow ptosis. Endolift laser method was used to treat the patients' upper eyelid and eyebrow ptosis. The biometric assessment was used to evaluate the efficiency of the technique. Also the results were evaluated by 3 board-certified dermatologists (blind). Additionally, patients' satisfaction was evaluated at the end of the treatment. The biometric results showed that Endolift laser can increase the thickness, density, and elasticity of the skin in the eyelid area. The patient's satisfaction results showed excellent improvement in the 90% of patients. The results by the dermatologist displayed improvement in about 90% of patient. Endolift laser has been proved efficient and consistent for upper eyelid and eyebrow ptosis rejuvenation and treatment.

KEYWORDS
Endolift laser, eyebrow, eyelid, laser, ptosis, treatment

1 | INTRODUCTION

An unusual drooping of the upper eyelid called blepharoptosis (ptosis) and can affect one or both eyes. Based on the appearance time, it is generally categorized as either congenital (existing at or shortly after birth) or acquired (appearing later in life). Blepharoptosis is being among the most common disorders of the eyelid that people suffered.[1,2] Drooping of the upper eyelid can caused asymmetry, in both bilateral and unilateral cases and also lead to the "sleepy" appearance of the patients.[3,4] This condition can have serious effects on patients' health and well-being, containing decreased self-confidence and increased anxiety and appearance-related depression.[5,6] The age is as a significant risk factor for the development of drooping of the upper eyelid in acquired Blepharoptosis.[1,2] The frontalis muscle, located at the eyebrow level, is innervated by the facial nerve. The contraction of this muscle raises the eyebrow, without having a direct effect on elevation of the upper eyelid. However, in the Blepharoptosis patients, compensatory raising of the eyebrows through the frontalis muscle can also indirectly elevate the eyelid slightly.[7] In most cases, upper eyelid ptosis is associated with eyebrows ptosis.[8] Currently, there are many treatment methods for eyebrow and upper eyelid lift. The most methods that used for Blepharoptosis treatment is surgical intervention. Elevation of the upper eyelid is

done with a variety of techniques that targeting the upper eyelid retractor muscles and aponeurosis.[9,10] Most of patients who seek blepharoplasty procedure have an eyebrow ptosis component with or without asymmetry.[8] Unlike upper and lower blepharoplasty, with a standard procedure[11,12] that is used almost universally, many surgical methods are available in the case of the eyebrows. These may be combined with upper blepharoplasty for long-lasting, stable, and natural results.[13] In the eyebrow lift technique, an invasive method is performed through plastic surgery in which the skin of the migraine area is pulled and sutures are used in the area, and another method is the use of lift floss that is used in the migraine area. However, the blepharoplasty and surgery are performed under injectable anesthesia. Sutures are used in the intervention area, and the patient needs complete rest and recovery time. Recently, the non-invasive techniques have received more attention. The laser-based treatment is one of non-invasive treatments that used for upper eyelid ptosis. Patients prefer to use the laser because of the blepharoplasty incisional aspects, as it is fast, is less probable to hurt the inferior oblique muscle, causes fewer sensory nerve stimulation, and has fundamentally no bleeding and consequently, less ecchymosis postoperatively. In this study, we used Endolift Laser as a non-invasive technique for treatment of upper eyelid and eyebrows ptosis.

2 | MATERIAL AND METHODS

2.1 | Subjects and eligibility criteria

9 healthy subject with moderate-to-severe upper eyelid and eyebrow ptosis underwent the Endolift laser procedures in our department. Patients ranged from 35 to 70 years old. Patients with: eye and eyelid inflammations; eyelid and eyebrow ptosis inventing from neurological or muscular impairments, additional cosmetic, or surgical procedures like peeling, Botulinum toxin A (BTA) or filer injection, ptosis correction, blepharoplasty, browpexy were not included in the study. Verbal explanations and written information about the scope and goals of the study were given to patients before the start of the treatment. The written informed consent and signed photograph and picture publication agreement were gained from the patient.

2.2 | Treatment technique

Endolift™ (LASEMAR1500TM machine, Eufoton s.r.l.) was utilized with the power of 75 W, energy: 600–800 J, pulse: 25, and fiber: 200–300 micron for each patient. Injectable or local anesthesia with lidocaine was applied before treatment. This procedure was performed one time and without any other technique. This technique doesn't need recovery time. The patients were followed up for 6 months after treatment.

2.3 | Assessment of treatment efficacy

2.3.1 | Biometric assessment

Visioface (D1000 ck, Cologne, Germany) photographs for each patient were taken with a digital camera before and 6 months after treatment. Patients biometric characteristics were evaluated by multi-probe adapter Cutometer (L parameter), (Courage +Khazaka Electronics, Cologne, Germany) and a skin ultrasound imaging system (TPM, Luneburg, Germany) to determine thickness of skin layers, and skin elasticity by providing R2, R5, R7 parameters, before and after treatment. The patients were followed up for 6 months after treatment.

2.4 | Objective evaluation

2.4.1 | Patients satisfaction

Photographs were taken before and 6 months after treatment. Patients were categorized into groups reflecting mild, moderate, good, and excellent improvement in upper eyelid and eyebrows ptosis. Regular photography (using a Nikon 10.2-megapixel camera) was also prepared for all patients at before and after treatment. Moreover, patients were requested to rate their satisfaction concerning the treatment and to inform any side effects. Patient satisfaction was evaluated and classified by a three-point Likert scale with the three anchors being satisfied, partially satisfied, or dissatisfied. All patients were followed up with 6 months after treatment.

2.4.2 | Physician assessment

The results of the treatment were measured by 3 board-certified dermatologists (blind). All patients were followed up with 6 months after their laser treatment.

2.5 | Statistical analysis

The results were analyzed by SPSS, version 22 (IBM Corp, Armonk, NY). A P value $<.05$ was considered to show statistical significance. The results were reported as percentages and mean ±SD (Standard Deviation).

3 | RESULTS

3.1 | Biometric characteristic results

In all patients, the results of biometric assessment before and 6 months after treatment were evaluated (Table 1). The Cutometer results displayed that the treatment cause increase in R2, R5, and R7

TABLE 1 Comparing biometric characteristics of the eyelid before and 6 months after the treatment

	Measured values			
	Before	After	Percent change	*p* value
Density[a]				
R2	0.60 ± 0.21	0.86 ± 0.13	43.33 ± 7.18	<0.05
R5	0.55 ± 0.22	0.76 ± 0.11	38.18 ± 11.32	<0.05
R7	0.48 ± 0.15	0.66 ± 0.15	37.5 ± 12.06	<0.05
Skin ultrasonography				
Skin density	13.06 ± 5.13	21.33 ± 4.15	63.32 ± 6.31	<0.05
Skin thickness	1010.21 ± 340.32	1300.15 ±102.06	28.70± 10.23	<0.05
Epidermis density	45.16 ± 10.91	62.36 ± 29.12	38.08 ± 12.01	<0.05
Epidermis thickness	43.40 ± 25.23	61.11 ± 11.25	40.80 ± 20.22	<0.05
Dermis density	15.60 ± 3.21	22.17 ± 11.12	42.11 ± 20.16	<0.05
Dermis thickness	995.75 ± 99.17	1390.30 ± 100.21	39.59 ± 11.31	<0.05

[a]Density of the skin measured by Cutometer.

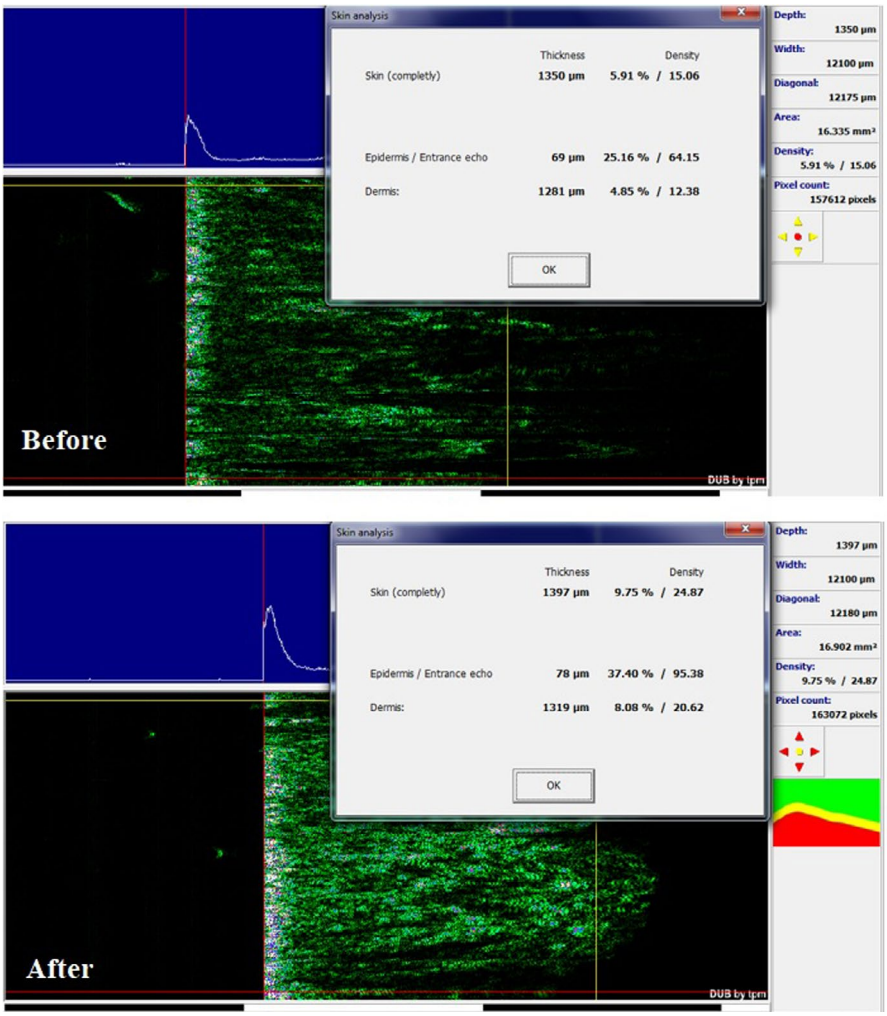

FIGURE 1 Skin ultrasonography in the patients before and after Endolift Laser treatment

parameters (Table 1), and there was a significant difference between the percentages changes of this parameter before and after Endolift laser treatment (43.33 ± 7.18), (38.18 ± 11.32), and (37.5 ± 12.06), ($p < 0.05$). The skin ultrasonography results indicated denser skin layers in the epidermis and dermis (Figure 1; Table 1). According to the results in Table 1, a significant increase in the density and thickness of epidermis and dermis was observed before and after treatment, and the percentage change that detected in the density and thickness of epidermis and dermis was as follow (38.08 ± 12.01), (40.80 ± 20.22), and (42.11 ± 20.16), (39.59 ± 11.31), respectively ($p<0.05$).

3.2 | Patient satisfaction

The mean score of patients' satisfaction after Endolift laser treatment is displayed in Table 2 According to the Antera scoring system, 90% of patients showed excellent improvement after treated with Endolift laser (Table 2).

TABLE 2 Improvement grad by Antera, 6 months after treatment was significant with *p* value <0.05

Improvement Grad	Endolift laser treatment	*p* value
Mild	1.1%	0.007
Moderate	2.1%	
Good	6.3%	
Excellent	90.5%	

3.3 | Physician assessment result

Regarding to the physicians' assessments (Table 3), the results displayed improvement in the 90% of patients. The results are shown in Table 3. Photographic documents revealed a significant improvement in all patients (Figure 2).

TABLE 3 The percentage of physician's satisfaction after 6 months

Endolift Laser treatment	Physician satisfaction (%) (Mean ± SD)	*p* value
Physician 1	91 ± 3.3	<0.05
Physician 2	85 ± 5.1	
Physician 3	90 ± 2.1	

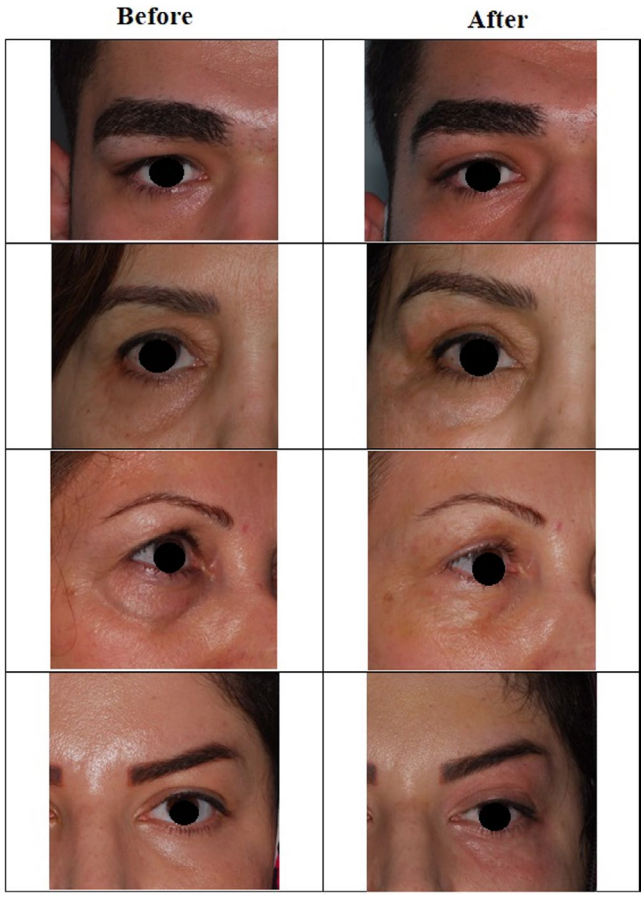

FIGURE 2 Before and 6 months after the Endolift treatment

4 | DISCUSSION

The stretching of the skin of the eyelids happens with aging. As skin ages, the skin progressively loses its elasticity. Lack of elasticity causes eyelids drooping (ptosis) and accumulation of excess skin in the upper eyelids.[14] Most of people with eyelid ptosis have a component of eyebrow ptosis with or without asymmetry. The people looking for facial rejuvenation focus on the periocular area, counting the skin laxity, and the drooping of upper eyelids and eyebrow. Different procedures have been used to safely achieve improvement of the upper eyelid and eyebrow ptosis.[15-18] Botulinum toxin A (BTA) injection may be used for eyebrow lifting but the effect is temporary and continues for about three to six months.[19] BTA injection might have some adverse effects like pain, bruising and ecchymosis, asymmetries, headache, focal facial paralysis, diplopia, dry eye syndrome, and muscle weakness.[19] Also, fillers can use to enhance eyebrow volume and contour, and, in case BTA fails to provide desired lifting of eyebrow, can be used for improving the lifting of the eyebrow tail.[20] Some complications that may happen with fillers are migration of filler material, ecchymosis and erythema, foreign body granulomas. Severe adverse events after fillers injection can be, biofilm reaction, infection, skin/tissue necrosis.[21] The most common treatment is surgery that usually done for cosmetic reasons. It is also an effective way to improve vision in older people whose drooping upper eyelids can affect their vision. Although, surgical methods to remove excess sagging skin were a way to rejuvenate but this is an invasive technique and needs recovery time and has side effects.[22] Blepharoplasty is a common cosmetic surgical intervention. Daniele Bollero was evaluated the safety and efficacy of blepharoplasty combined with suspension thread lifting on lifting facial tissues.[23] Ptosis surgery risks occasionally contain bleeding, infection, reduced vision, and over- or under correction. Also, instantly after surgery, there may be temporary troubles in wholly closing the eye. While the lid height improvement is usually succeeded, but the eyelids may not seem perfectly symmetrical. In some cases, the full movement of the eyelid does not return. Also, in some cases, more than one operation is needed. Currently, there is a tendency toward non-invasive methods in the case of rejuvenation surgery. So an alternative method for surgery is more attention now. Eyelid and eyebrow surgery are frequently performed for cosmetic reasons because it can increase self-confidence by improve of the self-appearance. Eyelid lift, or blepharoplasty, is an important part of any procedure of facial rejuvenation. Patients seeking facial rejuvenation are often concerned

about the risks of invasive facelift surgery like the usage of general anesthesia, wide dissection, extensive skin incisions, and recovery time. So, more patients are now opting for less invasive options that offer simultaneous treatment, acceleration, and optimization of recovery time.[24] Laser therapy is one of less invasive method for eyelid and eyebrow lift. In some study, the profits, efficacy, and safety of utilizing the CO2 laser to perform upper and lower eyelid cosmetic blepharoplasty were evaluated.[25-28] Endolift laser is a non-invasive procedure and is currently a great route for anti-aging and skin disorder treatment due to the rapid recovery, lack of wound, scarring, pain, and side effects.[29] In this study, the technique used for treatment of the upper eyelid and eyebrow ptosis was Endolift laser. Our study showed an enhanced outcome and patients' satisfaction. All patients demonstrated no complications and pain. Our results showed Endolift laser technique is efficient for correction and treatment of upper eyelid and eyebrow ptosis. The no complication rate and good results suggest that Endolift laser is successful technique for lifting the upper eyelid and eyebrow.

ACKNOWLEDGMENTS

We admiringly acknowledge the colleagues and staffs in Skin and Stem Cell Research Center, Tehran University of Medical Sciences, Tehran, Iran and Jordan Dermatology and Hair Transplantation Center, Tehran, Iran.

CONFLICTS OF INTEREST

The authors declare no conflicts of interest.

AUTHOR CONTRIBUTIONS

N. MA, B. E, L. E, and R. M performed the research. N. MA and N. N designed the research study. H-K.M analyzed the data and collected the data. N. M performed Biometric assessment.

DATA AVAILABILITY STATEMENT

Data are available on request from the authors.

ORCID

Mohammad Ali Nilforoushzadeh https://orcid.org/0000-0001-6143-8039
Maryam Heidari-Kharaji https://orcid.org/0000-0001-6954-7942
Elaheh Lotfi https://orcid.org/0000-0002-5262-0231

REFERENCES

1. Kim MH, Cho J, Zhao D, et al. Prevalence and associated factors of blepharoptosis in Korean adult population: The Korea National Health and Nutrition Examination Survey 2008–2011. *Eye*. 2017;31(6):940-946.
2. Hashemi H, Khabazkhoob M, Emamian MH, et al. The prevalence of ptosis in an Iranian adult population. *J Curr Ophthalmol*. 2016;28(3):142-145.
3. Finsterer J. Ptosis: causes, presentation, and management. *Aesthetic Plast Surg*. 2003;27(3):193-204.
4. Zoumalan CI, Lisman RD. Evaluation and management of unilateral ptosis and avoiding contralateral ptosis. *Aesthetic Surg J*. 2010;30(3):320-328.
5. McKean-Cowdin R, Varma R, Wu J, et al. Severity of visual field loss and health-related quality of life. *Am J Ophthalmol*. 2007;143(6):1013-1023.
6. Richards HS, Jenkinson E, Rumsey N, et al. The psychological well-being and appearance concerns of patients presenting with ptosis. *Eye*. 2014;28(3):296-302.
7. Hamedani AG, Gold DR. Eyelid dysfunction in neurodegenerative, neurogenetic, and neurometabolic disease. *Front in Neurol*. 2017;8:329.
8. Kashkouli MB, AbolfathZadeh N, Abdolalizadeh P, et al. Upper blepharoplasty and eyebrow position. *Expert Rev Ophthalmol*. 2017;12(3):251-259.
9. Pan ER, Chen W-L, Zhang S-C, et al. Mild to moderate blepharoptosis correction: outcomes of levator aponeurosis posterior layer plication. *Medicine*. 2020;99(12).
10. Cates CA, Tyers AG. Outcomes of anterior levator resection in congenital blepharoptosis. *Eye*. 2001;15(6):770-773.
11. Kashkouli MohsenBahmani, Jamshidian-Tehrani M, Sharzad S, et al. Upper blepharoplasty and lateral wound dehiscence. *Middle East Afr J Ophthalmol*. 2015;22(4):452.
12. Kashkouli MB, Pakdel F, Kiavash V, et al. Transconjunctival lower blepharoplasty: a 2-sided assessment of results and subjects' satisfaction. *Ophthalmic Plast Reconstr Surg*. 2013;29(4):249-255.
13. Karimi N, et al. Techniques of eyebrow lifting: a narrative review. *J Ophthalmic Vis Res*. 2020;15(2):218.
14. Brar B, Puri N. Blepharochalasis—a rare entity. *Dermatol Online J*. 2008;14(1).
15. Altieri M, Truscott E, Kingston AEH, et al. Ptosis secondary to anterior segment surgery and its repair in a two-year follow-up study. *Ophthalmologica*. 2005;219(3):129-135.
16. Battu VK, Meyer DR, Wobig JL. Improvement in subjective visual function and quality of life outcome measures after blepharoptosis surgery. *Am J Ophthalmol*. 1996;121(6):677-686.
17. Ben Simon GJ, MacEdo AA, Schwarcz RM, et al. Frontalis suspension for upper eyelid ptosis: evaluation of different surgical designs and suture material. *Am J Ophthalmol*. 2005;140(5):877-885.
18. Fagien S. Eyebrow analysis after blepharoplasty in patients with brow ptosis. *Ophthalmic Plast Reconstr Surg*. 1992;8(3):210-214.
19. Kashkouli MB, Amani A, Jamshidian-Tehrani M, et al. Eighteen-point abobotulinum toxin a upper face rejuvenation: an eye plastic perspective on 845 subjects. *Ophthalmic Plast Reconstr Surg*. 2014;30(3):219-224.
20. Raspaldo H, Gassia V, Niforos F-R, et al. Global, 3-dimensional approach to natural rejuvenation: part 1–recommendations for volume restoration and the periocular area. *J Cosmet Dermatol*. 2012;11(4):279-289.
21. Chiang Y, Pierone G, Al-Niaimi F. Dermal fillers: pathophysiology, prevention and treatment of complications. *J Eur Acad Dermatol Venereol*. 2017;31(3):405-413.
22. Romeo F. Upper eyelid filling with or without surgical treatment. *Aesthetic Plast Surg*. 2016;40(2):223-235.
23. Bollero D. Jawline reshape technique with suspension threads to improve the effect of blepharoplasty on face rejuvenation. *J Cosmet Dermatol*. 2021;20:12-17.
24. Kaminer MS, et al. Long-term efficacy of anchored barbed sutures in the face and neck. *Dermatol Surg*. 2008;34(8):1041-1047.
25. David LM, Abergel RP. Carbon dioxide laser blepharoplasty: conjunctival temperature during surgery. *J Dermatologic Surg Oncol*. 1989;15(4):421-423.
26. David LM. The laser approach to blepharoplasty. *J Dermatologic Surg Oncol*. 1988;14(7):741-746.
27. Fallahi HR, Keyhan SO, Niamtu J, et al. Comparison of clinical outcomes of CO_2 laser-assisted blepharoplasty using two different methods. *J Oral Maxillofac Surg*. 2020;78(6):1006-1012.

28. Langelier NA, Liss J, Leyngold IM, et al. CO_2 laser lash tilt technique for the treatment of mild to moderate lash ptosis and augmentation of upper eyelid blepharoplasty results. *Ophthalmic Plast Reconstr Surg*. 2019;35(4):399-402.
29. Nilforoushzadeh MA, Fakhim T, Heidari-Kharaji M, et al. Efficacy evaluation of Endolift-based Subcision on acne scar treatment. *J Cosmet Dermatol*. 2021;20(8):2579-2582.

How to cite this article: Nilforoushzadeh MA, Heidari-Kharaji M, Behrangi E, et al. Effect of Endolift laser on upper eyelid and eyebrow ptosis treatment. *J Cosmet Dermatol*. 2022;00:1–6. doi:10.1111/jocd.14798